

Our Experiences on Injuries due to Corrosive Intake

Sibel Ozkan Gurdal, Tayfun Yucel, Mustafa Oran, Gursel Remzi Soybir, Ferda Nihat Koksoy, Rafet Mete

ABSTRACT

Background: The aim is to present our experiences on the treatment and follow-up in the injuries of corrosive intake.

Materials and methods: Twelve patients who were admitted to clinics because of swallowed corrosive substance between year 2005 and 2010 were evaluated retrospectively.

Results: According to the findings of esophagogastro-duodenoscopies performed in the first in 12 to 24 hours, none of the patients had grade III esophageal injuries but only one patient who had grade III stomach injury was operated urgently and total gastrectomy + Roux-en-Y esophagojejunostomy was performed. The others that were grades I and II were managed conservatively. During the follow-up period, all patients were controlled with clinic and endoscopic examinations in 1st and 3rd months.

Conclusion: These patients were managed by the teams of general surgeon, and head and neck surgeons urgently. Early esofagogastroscopy was so important for the treatment strategy of these patients.

Keywords: Corrosive, Gastrointestinal burn, Esophageal lesions, Management.

How to cite this article: Gurdal SO, Yucel T, Oran M, Soybir GR, Koksoy FN, Mete R. Our Experiences on Injuries due to Corrosive Intake. *Euroasian J Hepato-Gastroenterol* 2013; 3(1):46-48.

Source of support: Nil

Conflict of interest: None

INTRODUCTION

Intake of corrosive substances is specially seen in childhood period. In adults it is mostly seen in suicide cases.^{1,2} In the 75 to 90% of cases alkaline intake is seen and of these sodium and potassium hydroxide are the most common ones. Sulfuric acid is the most ingested acid. They frequently cause erythema, ulcer or necrosis and sometimes lesions that lead to perforation in stomach and esophagus. We aimed to assess corrosive substance intake cases of our clinics in the light of the recent literature.

MATERIALS AND METHODS

Between years 2005 and 2010, 12 patients were admitted to general surgery and gastroenterology clinics of Taksim Educational and Research Hospital and Namik Kemal University Educational, Research and Treatment Center, respectively for corrosive substance intake. Five (41.6%) patients were male, seven (58.4%) patients were female and median age was 25 (14-38). Four of them were suicidal and eight of them were accidental intake cases. All cases had

low socioeconomic status and have been lived in the suburbs. All cases have immediately admitted to the centers after intake. Nine patients (73%) had taken acid, three patient (27%) had taken alkaline substances. After having ensured whether they had airway obstruction or not intravenous access was opened. Without provoking vomiting and applying nasogastric tube, patients were encouraged for oral water intake and intravenous fluid replacement started. Complete blood count, posterior anterior chest and plain abdominal X-ray were performed to all subjects, and they were consulted by otorhinolaryngologist. H₂ receptor blockers (2 × 40 mg/day), cefazolin sodium (3 × 1 gm/day) was started. Intravenous corticosteroids were given to two patients because of uvula edema and in the early period (12-24 hours) esophagogastroduodenoscopies were performed to all patients (Fig. 1). Results were assessed according Kirkendall's classification¹ in four grades (Table 1). Patients were controlled by using radiologic methods and endoscopy at the 1st and 3rd month during follow-up.

FINDINGS

Patients were hospitalized following physical examination. All patients were suffering dysphagia and epigastric pain. None of the patients had acute abdomen or thoracic pain. Two cases (18%) had leukocytosis. Uvula edema was found in two cases (18%). Conservative treatment was started. No pathology was observed in posterior anterior chest and plain abdominal X-ray of all patients. Findings of

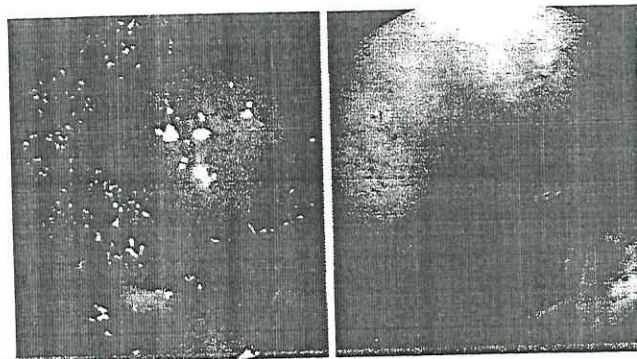


Fig. 1: Grade I gastric and esophageal burn

Table 1: Kirkendall's classification

Grade I	Edema and erythema of the mucosa
Grade IIA	Hemorrhage, erosions, blisters, superficial ulcers
Grade IIB	Circumferential lesions
Grade III	Deep gray or brownish-black ulcers
Grade IV	Perforation

esophagogastroduodenoscopies performed in the first 12 to 24 hours are listed in Table 2.

Grade III esophageal injury was not found in any patients but grade III gastric injury was observed. Patient with grade II esophageal and grade III gastric injury immediately underwent surgery and gastrectomy + Roux-en-Y esophagojejunostomy was performed (Fig. 2). Postoperative period was managed unremarkably. Other patients were treated conservatively. They were discharged after 2 days, approximately.

During follow-up, no pathology was seen in the control passage X-ray and endoscopy of the patients done 4 weeks after injury as well as at the third month in all cases.

DISCUSSION

Patients with corrosive intake commonly complain hypersalivation and dysphagia, however in our patients epigastric pain and dysphagia were more common. In accordance with the literature most of the patients had low socioeconomic status and had taken the substance by accident. Since the patient's maintenance of airway and breathing is the main goal, first examination with an otorhinolaryngologist is important.²⁻⁴

Oral intake must be stopped and vomiting should be avoided because vomiting may cause increased damage

Table 2: Esophageal findings (EF) and gastric findings (GF)

Ingested substance	Acid	Alkaline
Number	9	3
Normal EF and GF	4	0
Grade I EF	3	2
Grade I GF	2	3
Grade II EF	2	1
Grade II GF	2	0
Grade III EF	0	0
Grade III GF	1	0

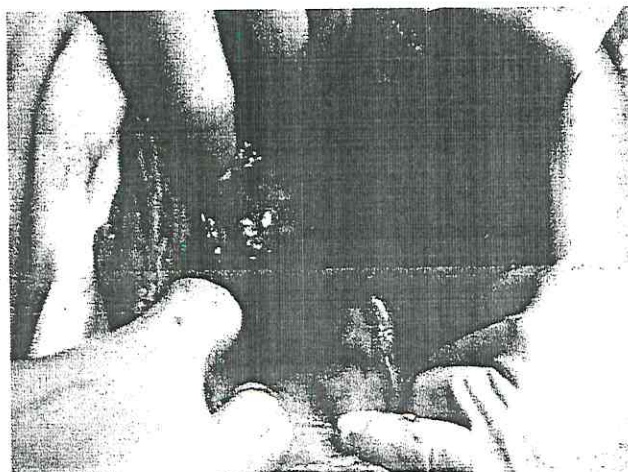


Fig. 2: Grade III gastric injury

by recontacting of corrosive substance with mucosa and risk of aspiration pneumonia may increase. It has been suggested that milk intake in acid ingestion and lemon or orange juice in alkaline ingestion may dilute and partially neutralize corrosive substance, on the contrary some supports avoidance of any oral intake because gastric dilatation, vomiting and exacerbation of the exothermic reaction of affected tissues may occur.⁴⁻⁷ Our practice do not use any of these drinkings.

Intravenous access should be opened and intravenous fluid replacement and H₂ receptor blocker treatment should be started.³⁻⁸ Esophagogastrosopy in first 12 hours and rating of the observed lesions according to Table 1 are recommended,⁹ so we did the same. In most of the suicidal cases serious gastrointestinal findings could be seen. Our patient which was operated because of grade III gastric and esophagus injury was the suicidal case. Results of accidental intake cases are known to be much better.⁴ Patients possess grade I and II injuries of gastrointestinal system, similar in most cases of us, may be discharged after a 24- to 48-hour observation period. However, it should not be forgotten that severity of necrosis in the gastrointestinal tract may not be allways well defined by endoscopy. Therefore thoracoscopy and laparoscopic investigations are recommended if needed.² In grade III injuries some suggest laparotomy primarily and resection or applying a stent to esophagus for preventing stricture in the presence of any lesion in esophagus.¹⁰ It is well known that in most cases gastric necrosis (especially antrum) is observed however due to the quick passage of corrosive substance through the esophagus full thickness injury of it is rare even though in the presence of mucosal damage. Some authors recommend surgery if endoscopic findings are supported by clinical (acute abdomen) and radiological findings (free air sign in abdominal plain X-ray, etc).^{2,9-12} Mucosal necrosis (grade II injury) in esophagus, necrosis and perforation (grade III injury) in stomach were observed in the esophagogastroduodenoscopy of a patient in our series. This patient was operated immediately and full thickness gastric necrosis was observed. Muscular and adventitial layers of abdominal esophagus were found to be intact in the ongoing exploration. It is possible to assess esophageal wall during the laparotomy. Gastrectomy and Roux-en-Y esophagojejunostomy was performed in this case. Quick passage of the corrosive substance through esophagus mostly causes just mucosal lesions but the accumulation of the substance in stomach may cause full thickness gastric necrosis and perforation.⁷⁻¹⁰ Therefore gastric resection (limited or total) is the most applied operation in these cases.^{2,8,11,13} In our case, just gastric resection was

performed and any intervention to esophagus was not needed. In the postoperative follow-up period no problem was observed.

Corticosteroid treatment is thought to be beneficial to prevent stricture in grade II injury and stent implantation is recommended by some authors in these cases.¹⁴ We did not give any corticosteroid treatment except two patients with uvula edema. No problem, specially stricture, was not found in the 1st and 3rd months control of any cases.

As a result, corrosive substance intake accidentally or committing suicide are common in the population. Otorhinolaryngologic and endoscopic evaluations of the patients at the early period and conservative treatment is frequently sufficient. Necrosis is mostly seen in stomach and early resection of the necrosed and perforated gastric segment is life saving.¹⁵

REFERENCES

1. Kikendall JW. Caustic ingestion injuries. *Gastroenterol Clin North Am* 1991;20:847-57.
2. Lu A, Altorki N. Caustic burns of the esophagus. In: Cameron JL (Ed). *Current surgical therapy*. Philadelphia: WB Saunders 1998:55-58.
3. Lai KH, Huang BS, Huang MH, Huang MS, Wu JK, Liu M, et al. Emergency surgical intervention for severe corrosive injuries of the upper digestive tract. *Chung Hua Hsueh Tsa Chih* 1995;56(1):40-46.
4. Ertekin C, Ayдын E, Tavilođlu K, Gulođlu R, Kurtođlu M. Korozif madde alıymy sonrası geliđen ozofagus ve mide yanıkclarına yaklapım. *Ulusal Cerrahi Dergisi* 2001;17(5): 300-07.
5. Skinner DB. Perforation of the esophagus: Spontaneous (Boerhaave's syndrome), traumatic and following esophagoscopy. In: Sabiston DC (Ed). *Textbook of surgery*. Philadelphia: WB Saunders 1997:749-53.
6. Moore WR. Caustic ingestions. Pathophysiology, diagnosis and treatment. *Clin Pediatr* 1986;25(4):192-96.
7. Mamede RC, De Mello Filho FV. Treatment of caustic ingestions:an analysis of 239 cases. *Dis Esophagus* 2002; 15(3):210-13.
8. Karaođlu OA, Ozutemiz O, Ylter T, Batur N, Yonetci O. Akut korozif Ozofajit: 108 Olgunun Dederlendirilmesi. *Gastroenteroloji* 1996;7(1):1-4.
9. Yannettoni MD, Stirling MC, Orringer MB. Esophadgeal trauma. In: Zuidema GD (Ed). *Shackelford's surgery of the alimentary tract*. Philadelphia: WB Saunders 1996:482-85.
10. Wijburg FA, Beukers MM, Heymans HS, et al. Nasogastric intubation as sole treatment of caustic esophageal lesions. *Ann Otol Rhinol Laryngol* 1985;94(4):337-41.
11. Andreoni B, Farina ML, Biffi R, Crosta C. Esophageal perforation and caustic injury: Emergency management of caustic ingestion. *Dis Esophagus* 1997;10(2):95-100.
12. Munoz Bongrad N, Gomet JM, Sarfati E. Diagnostic and therapeutic management of digestive caustic burns. *J Chir* 2002;139(2):72-76.
13. Javed A, Pal S, Krishnan EK, Sahni P, Chattopadhyay TK. Surgical management and outcomes of severe gastrointestinal injuries due to corrosive ingestion. *World J Gastrointest Surg* 2012; 27;4(5):121-25.
14. Ramasamy K, Gumaste VV. Corrosive ingestions in adults. *J Clin Gastroenterol* 2003;37(2):119-24.
15. Chibishev A, Pereska Z, Chibisheva V, Simonovska N. Corrosive poisonings in adults. *Mat Soc Med* 2012;24(2): 125-30.

ABOUT THE AUTHORS

Sibel Ozkan Gurdal (Corresponding Author)

Medical Faculty, Department of General Surgery, Namik Kemal University, Tekirda—Turkey, Phone: 00905322307988, e-mail: drasog@yahoo.com

Tayfun Yucel

Professor, Department of General Surgery, Kartal Training and Research Hospital. Istanbul. Turkey

Mustafa Oran

Medical Faculty, Department of Internal Medicine, Namik Kemal University, Tekirda—Turkey

Gursel Remzi Soybir

Medical Faculty, Department of General Surgery, Namik Kemal University, Tekirda—Turkey

Ferda Nihat Koksoy

Department of General Surgery, Taksim Training and Research Hospital. Istanbul. Turkey

Rafet Mete

Medical Faculty, Department of Gastroenterology, Namik Kemal University, Tekirda—Turkey